

Quiz Section

(Quiz No. 2, Vol. 04)

S. G. Gandage, V. D. Aironi, Department of Radiology, RMC, Loni

Brief History:

A six year old girl came for B-scan to Department of Radiology. She had leukocoria and microphthalmia of right eye since birth. The right eye is blind. A B-scan was performed by using 10 MHz linear ultrasound probe on Siemens Sonoline Ultrasound machine. The following images show the underlying condition.

What is your diagnosis?

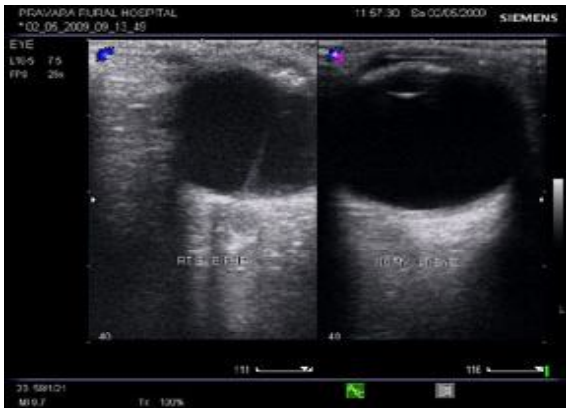


Figure 1: B-scan of both eyes

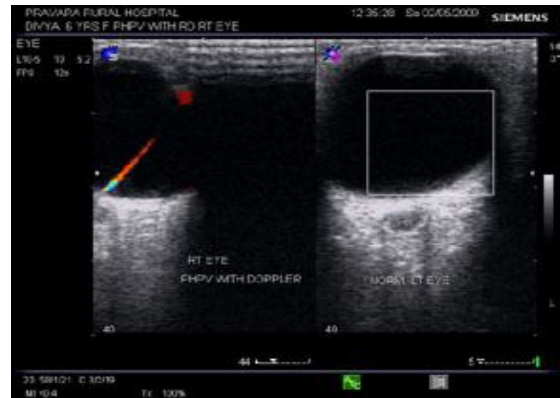


Figure 2: Colour Doppler of right eye

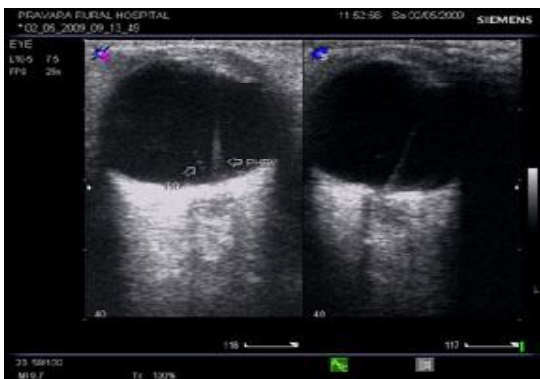


Figure 3: B-scan of right eye

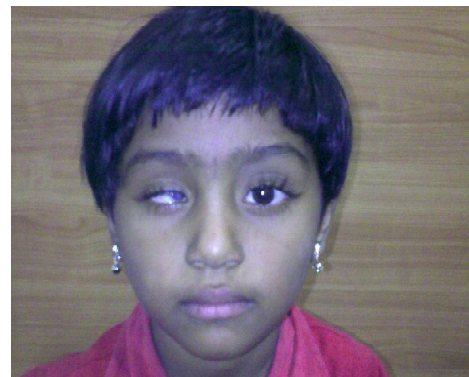


Figure 4: The photograph of the patient