

RAPUNZEL SYNDROME WITH SUPERIOR MESENTERIC ARTERY SYNDROME: A CASE REPORT AND REVIEW OF THE LITERATURE

S.G.GANDAGE, V.D.AIRONI, N.RAM PRASANNA NAIK, SUNIL KUMAR.N

Abstract

We report a case of Rapunzel syndrome, an unusual rare gastro-intestinal trichobezoar extending into the ileum with Superior mesenteric artery syndrome in a five year old boy, presenting with a history of pain and distension of upper abdomen since four months. His parents gave history of intermittent vomiting and ingestion of hairs and threads. He was investigated with ultrasound of abdomen, barium meal and computed tomography (CT) which revealed gastrointestinal trichobezoar extending into distal ileum (Rapunzel syndrome) with Superior mesenteric artery syndrome (SMA). The patient underwent gastrotomy which revealed a trichobezoar extending into the distal ileum with SMA syndrome, confirming our radiological diagnosis. The mode of presentation and appearance on various imaging modalities like ultrasound, Barium meal and Computed tomography are discussed.

Key Words: *Rapunzel syndrome, Superior mesentric artery syndrome, Trichobezoar*

Introduction

Rapunzel syndrome is unusual, rare presentation of trichobezoar extending from stomach and duodenum into the distal ileum. It was first described and coined by Vaughan and associates in 1968^[1]. Rapunzel syndrome is named after the long haired girl named Rapunzel in the fairy tale by the Brothers Grimm. The term "bezoar" is derived from Arabic "badzehr" or from Persian "panzehr", both meaning counter poison and antidote^[2]. Here we present a case of this condition and the usefulness of ultrasound, Barium meal and Computed tomography in proving this condition.

Case Report

A five year old boy presented to radiology department for investigation of a lump in his abdomen with history of pain and distension of upper abdomen. He had

intermittent vomiting and had a history of ingestion of hairs. On examination, a firm epigastric lump was palpable. We investigated the boy with various imaging modalities like ultrasound, Barium meal and computed tomography (CT).

On imaging, ultrasound of abdomen demonstrated a superficially located broad band of high amplitude echoes along the anterior wall of the mass with a sharp clean posterior acoustic shadowing (Figure 1). Then

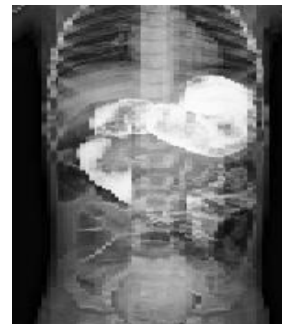

Figure 1: Barium meal study reveals filling defects in the stomach, duodenum and small bowel with partial obstruction of third part of duodenum, due to SMA syndrome.

Address for correspondence:

Dr. S.G.Gandage, Department of Radiology, Rural Medical College, Pravara Institute of Medical Sciences, Loni, Taluka - Rahata, Ahmednagar, Maharashtra-413 736, India.
E-mail: radiology@pmtpims.org

the patient was subjected to upper gastrointestinal barium series, which revealed large, mottled, filling defects in stomach, duodenum and small intestine (Figure 2). The third part of duodenum revealed vertical

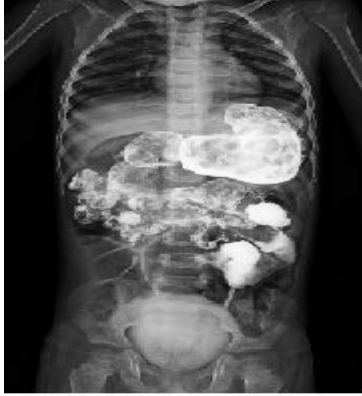

Figure 2: Barium meal and follow-through study confirms the filling defects in small bowel also.

filling defect with abrupt transition into normal caliber jejunum, suggesting co-existent superior mesenteric artery syndrome. This was confirmed on ultrasound which revealed reduced angle between superior mesenteric artery and aorta, causing partial obstruction of third part of duodenum (Figure3 & 4).

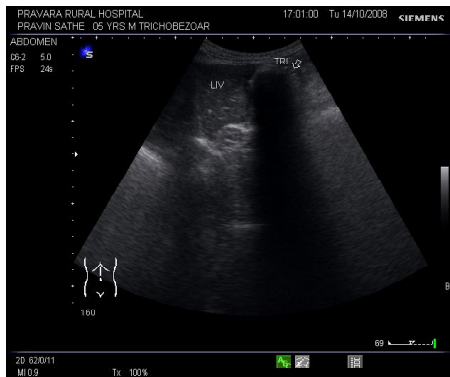


Figure 3: Ultrasound study of upper abdomen reveals dense echogenic area in epigastrium with sharp posterior acoustic shadowing.

Computed tomography (CT) of abdomen was performed for better demonstration of the lesion. Non contrast computed tomography revealed a large heterogeneous well circumscribed lesion, composed

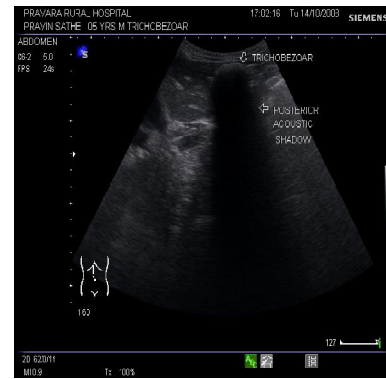


Figure 4: Ultrasound examination in longitudinal section reveals the echogenic filling defect in stomach with sharp posterior acoustic shadowing.

of concentric whorls, which had multiple pockets of air enmeshed within the mass lesion involving the stomach, duodenum and small intestine. A crescent of air was seen peripherally along the non-dependent part of the lesion. On post contrast CT study, the lesion is non-enhancing and the normal stomach wall is seen separately from the mass lesion (Figure5 & 6).

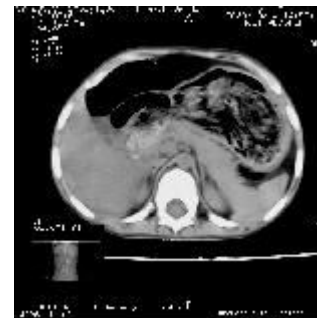

Figure 5: Computed tomography of abdomen reveals filling defects in stomach showing concentric rings, mixed density areas and trapped air with the intra-gastric mass.

Gastrotomy was done and the presence of trichobezoar was confirmed, which revealed a large trichobezoar in the stomach and duodenum with extension into the ileum. The mass is composed of long strands of hair and threads that formed a long tail extending into the ileum which was removed by gastrotomy. Superior

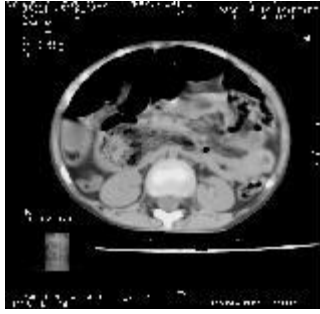


Figure 6: Computed tomography of abdomen reveals filling defects in small bowel showing trapped air within and mixed density pattern.

mesenteric artery syndrome was also confirmed, seen as reduced angle between superior mesenteric artery and aorta with consequent compression of third part of duodenum.

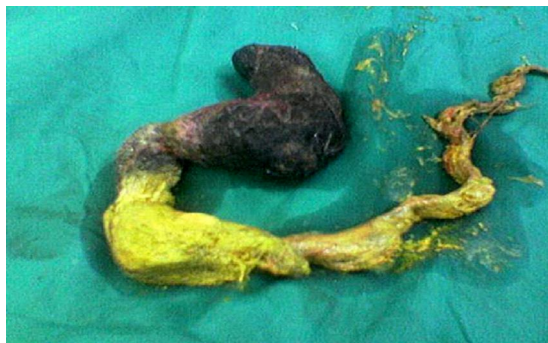

Figure 7: Surgical specimen reveals large trichobezoar removed from stomach, duodenum and small bowel.

Discussion

Ingested materials accumulate in the stomach and form nonopaque foreign bodies called bezoars. The term “bezoar” is derived from Arabic “badzehr” or from Persian “panzehr”, both meaning counter poison and antidote. Hindus used bezoars as antidote for neutralizing snake venoms and other poisons. Trichobezoar is derived from word ‘trich’ meaning hairs in Greek^[11]. The first description of a post-mortem human bezoar was given by Swain in 1854^[3]. Trichobezoars or hairballs result usually from the swallowing of hair plucked from head or fibers from

fur rugs, garments, or woolen clothing and blankets. Bezoars usually occur in psychologically disturbed young women or mentally retarded children who have disorder called trichotillomania (hair plucking) and trichophagia (ingestion of hairs)^[11]. They can also develop in individuals with history of vagotomy, gastric dysmotility and partial gastrectomy in the past^[12]. Phytobezoars develop on ingestion of vegetable fibers^[12], whereas lactobezoars occur in premature babies fed with thick milk supplements. In such patients, over a period of time, an intraluminal mass develops, representing matted indigestible hair and trapped food particles, taking the shape of stomach^[4]. Very rarely the trichobezoar can be very long and extend down to the terminal ileum or even transverse colon in which case the condition is referred to as the Rapunzel syndrome. Rapunzel syndrome is named after a beautiful long haired girl name Rapunzel in a German fairy tale by Grimm brothers^[10,11], (published in 1812) in which Rapunzel let her long golden hair down the prison in the castle over which her lover prince climbed upon to rescue her^[11]. The common complaints include abdominal pain, nausea and bloating, early satiety and weight loss. Rarely perforation of bowel or intussusception can occur^[12]

Ultrasound, gastrointestinal barium studies and computed tomography are reliable methods of diagnosing gastrointestinal trichobezoars. Ultrasound is the primary imaging modality for evaluation of an upper abdominal mass in children which will demonstrate a superficially located broad band of high amplitude echoes along the anterior wall of mass with sharp, clean posterior acoustic shadowing^[5,6]. Upper GI barium series clearly identify these lesions which typically produce filling defects in the stomach, duodenum and ileum after the ingestion of barium. After the free barium has expelled from the stomach, the barium that has adhered to the surface of the bezoar, and has absorbed by it, casts a persistent, mottled shadow of increased density^[7]. Plain abdominal CT scan usually shows an intragastric mass consisting of compressed concentric rings with mixed density pattern. The demonstration of normal gastric wall and the free mobility of the mass on rescanning, after alteration of patient’s position and

administration of oral contrast medium, rule out the origin from the gastric wall^[6].

Superior mesenteric artery syndrome represents partial obstruction of duodenum by superior mesenteric artery because of reduced angle between aorta and superior mesenteric artery^[13]. This occurs due to loss of retroperitoneal fat as a result of starvation and malnutrition or even due to severe burns^[13, 14]. It is treated by performing duodenotomy and reanastomosis of duodenum to relieve the obstruction. In this case, SMA syndrome may be due to severe malnutrition as a result of longstanding trichobezoar. The treatment of small bezoars may be amenable to nasogastric lavage or suction, clear liquid diet and the use of prokinetic agents^[8]. Most of the trichobezoars however, require surgery for removal. The standard treatment is a gastrotomy and extraction of bezoar. Duncan et al^[9] recommended extraction of bezoar by multiple enterotomies in cases of Rapunzel syndrome. Psychiatrist referral is a must in suspected individuals.

Conclusion

We described a very rare variety of trichobezoar, the Rapunzel syndrome in association with SMA syndrome which is an extremely uncommon. The diagnosis of Rapunzel syndrome with SMA syndrome on imaging was possible only because of multi-modality approach towards diagnosis. The characteristic appearance of trichobezoars on ultrasound, GI barium studies and computed tomography helps us in diagnosing the same.

References

- 1) Naik S, Gupta V, Naik S, et al. Rapunzel syndrome reviewed and redefined. *Dig Surg*. 2007; 157-161
- 2) Williams RS. The fascinating history of bezoars. *Med J Aust* 1986; 145: 613-614
- 3) Chisholm EM, Leong HT, Chung SC, Li AK. Phytobezoars: An uncommon cause of small bowel obstruction. *Ann R Surg Engl* 1992; 74: 342-344
- 4) *Imaging of the new born, infant and young child; 5th edition* (2004) Leonard E Swischuk.
- 5) McCracken S, Jongeward R, Silver TM, Jafri SZH. Gastric trichobezoar: Sonographic findings. *Radiology* 1986; 161: 123-124
- 6) Narinder K Kaushik, Yash P Sharma, Asha Negi, Amal Jaswal. Images: Gastric trichobezoar. *Indian J Radiol Imaging* 1999; 9: 137-139
- 7) Caffey's pediatric X ray diagnosis: An integrated imaging approach; 9th edition. Bezoars: 1052-1053. (1993). Fredric N Silverman, Jerald. P. Kuhn
- 8) Philips MR, Zaheer S, Drugas GT. Gastric Trichobezoar: case report and literature review. *Mayo Clinic Proc* 1998, 73: 653-656
- 9) Duncan ND, Aitken R, Venugopal S, et al. The Rapunzel syndrome. Report of a case and review of the literature. *West Indian Med J*. 1994; 43:63-65.
- 10) Iman Hamza et al, Rapunzel syndrome, *Arab journal of gastroenterology* 2007; 8(3): 99-100
- 11) Mohammed E. Rabie et al, Rapunzel syndrome: The unsuspected culprit, *World J Gastroenterol* 2008 February 21; 14(7): 1141-1143
- 12) Dr. Kishor Taori et al, Rapunzel syndrome, *Applied Radiology Online(Pediatrics)*
- 13) *Textbook of Ultrasonography* by David Cosgrove.
- 14) *Textbook of Radiology and Imaging* by David Sutton.