

CONGENITAL ANOMALY OF KIDNEY AND URETER – A CASE REPORT

Dr. S. K. Chavan, Dr. C. V. Diwan

Abstract

Congenital anomalies of urinary tract are of frequent occurrence. These anomalies were found during human cadaveric dissection carried out in the Department of Anatomy, S. R. T. R. Medical College, Ambajogai. In place of right kidney, a small triangular fibrous structure of size 3x2 cm² with a thread like ureter coursing normally and entering a normal sized urinary bladder was found. The left kidney was larger in size with normally coursing ureter. The right ureter was thinner and did not open in the urinary bladder while the left ureter displayed an abnormally low placed left ureteric opening. The testis and their duct system were normal. Right and left suprarenals were normal in position and size. Abnormal right ureter and fibrous triangular structure were studied histologically by preparing Hematoxylin & Eosin stained sections. Ureter showed normal histology with muscular coat and transitional epithelial lining, while the fibrous mass showed an attempt towards formation of renal tubules, mesenchymatous fibrous tissue and also tubules showing appearance of epididymis with typical high columnar epithelium. Unilateral renal agenesis is a commonly reported anomaly although it is always associated with absence of ureters. The presence of epididymis like tubules with normal male genital duct system and the, fibrous mass replacing the right kidney, raise doubtful developmental queries. Probable causes leading to such anomalies have been discussed.

Key words: Congenital, Anomaly, Kidney, Ureter

Introduction

Embryologically and anatomically urinary and genital system are intimately interwoven, both developing from a common mesodermal ridge i.e. intermediate mesoderm and initially the excretory duct of both the systems enter a common cavity, the cloaca. Overlapping of the two systems is particularly evident in male. The primitive excretory duct first functions as a urinary duct but later transforms into the main genital duct. Unilateral renal agenesis is relatively of common occurrence, about one in every 1000 new born infants^[1]. Males are affected more often than female.

Unilateral absence of kidney often causes no symptoms and is usually not discovered during infancy because the other kidney undergoes compensatory hypertrophy and performs the function of missing kidney.

Case History and findings

The case was observed in a male of nearly 50 to 55 years of age. The cause of death was unknown. The right kidney was anomalous. Instead of the normal right kidney a small triangular mass of size 3 X 2 cm² and 2 to 3 mm in thickness was found (Fig. 1). The ureter of this kidney was normal in its course but was thread like and ended blindly in the urinary bladder. The right renal vessels were also of smaller in diameter but normal in their course (Fig.1). The left kidney was little larger in size 11.5 cm in length and 6 cm in breadth.

Address for correspondence:

Dr. S K Chavan Department of Anatomy, Rural Medical College, Pravara Institute of Medical Sciences, Loni, Taluka - Rahata, Ahmednagar, Maharashtra-413 736, India.
E-mail: anatomy@pmpims.org

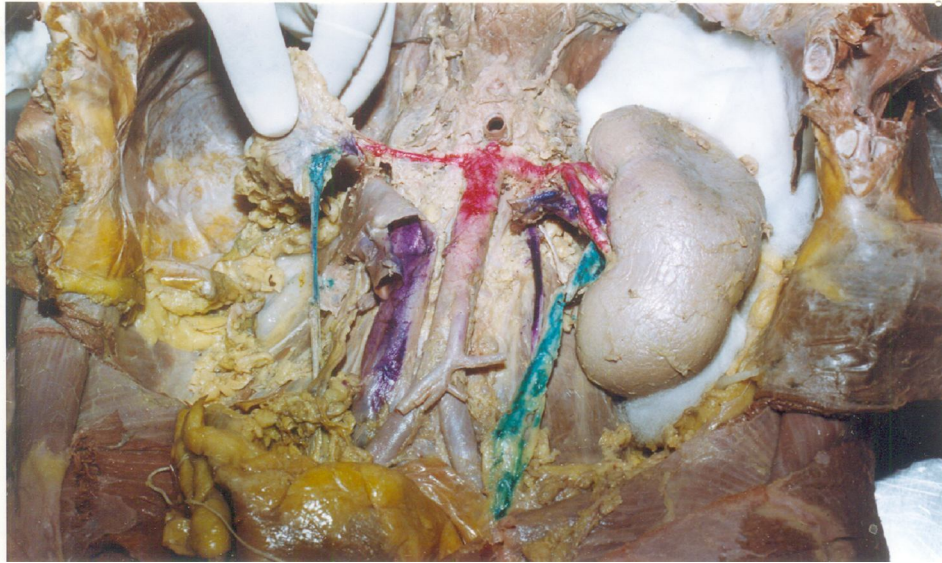


Fig. 1: Photograph showing small triangle mass, ureter and renal artery of smaller diameter of right kidney.

Dye was injected with the syringe first in right and then in left ureter to see the position of ureteric openings in the trigone of the bladder wall. Normally the ureteric openings are slit like and are placed at superolateral angles of the trigone. In this case no dye leaked after the right ureter was injected indicating that the right ureter ended blindly in the bladder wall. On the left side dye was seen leaking through an abnormally low placed left ureteric opening. The urinary bladder was normal in size. The right and left suprarenal were normal in position and size. Testis and their duct systems were normal.

The cross sections of the triangular mass could not be taken because of thinness of the tissue mass. Abnormal right ureter and fibrous triangular mass were studied histologically by preparing Heamatoxylin and eosin sections. Right ureter showed normal histology with muscular coat and transitional epithelium, though lumen showed fibrotic changes. In the fibrous mass tubules with stratified arrangement of cells similar in appearance to seminiferous tubular epithelium was observed (Fig.2). In addition plenty of mesenchymatous tissue (small fibers and lots of nuclei of mesenchymal cells) was present in the spaces between the tubules (Fig. 3). Some tubules lined with high columnar ciliated epithelium were also seen.

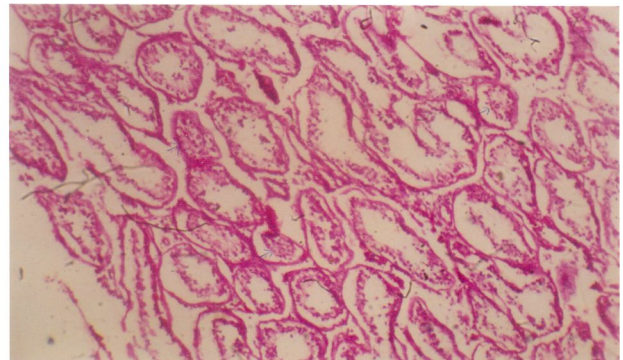


Fig. 2: Photomicrograph showing stratified arrangement of epithelium.

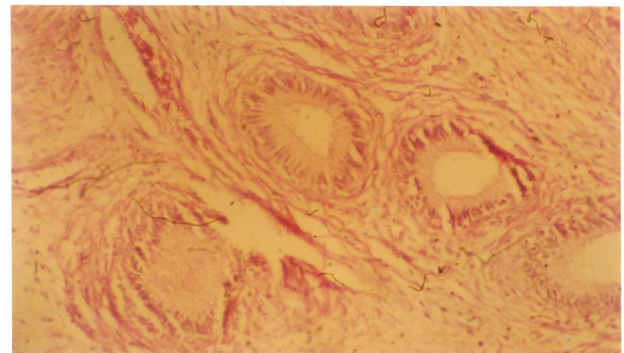


Fig. 3: Photomicrograph showing some of the tubules lined by high columnar ciliated epithelium.

Discussion

In unilateral renal agenesis complete absence of one of the kidney is common and is usually the left kidney is absent^[2]. In the present case left kidney was present but the right kidney could not develop upto its fullest extent and the compensatory hypertrophy of left kidney took place. Histologically right kidney showed an attempt towards formation of nephrogenic vesicles and glomeruli from the metanephric blastema. In the initial stage of development from 5th to 14th week each ampulla induces the formation of a nephrogenic vesicle which then fuses with its ampulla and differentiates into a nephron. When this ampulla divides one of it retains the nephron while other ampulla induces the formation of new nephron from nephrogenic blastema. Abnormal kidney may arise from abnormal inductive interactions. In some cases subtle defects between ureteric bud and metanephric blastema results in hyperplasia or dysplasia of the developing kidney^[3]. Here in this case probably ampulla upto some generations could induce the nephron formation but later due to some reason ceased to divide, so further development of nephrogenic blastema was arrested resulting in an atretic kidney. The failure of differentiation of metanephric blastema on right side may be due to local vascular insufficiency. Other causes such as genetic or other teratogenic influences can be ruled out as left kidney developed normally. From the nephrogenic blastema some blastema cells arranged themselves to form hollow vesicles but could not form blastimal cap for the next subdivision of ampulla. The small number of nephron in the hyperplastic kidney results either from inadequate branching of the ureteric bud or from an inadequate response by the metanephric cap tissue. In case of renal dysplasia, the nephron themselves develops abnormally and consists of primitive ducts lined by undifferentiated epithelial sheath

within thick layer of connective tissue^[3]. The right ureter also suffered and its canalization was not proper so that it ended blindly in the bladder wall^[4].

Left ureter had abnormally low placed ureteric opening. Normally common excretory duct is absorbed into the dorsal wall of vesico urethral canal and as a result the mesonephric duct and ureters open separately into the canal. As development proceeds, ureteric orifices move cranially and laterally in relation to the opening of mesonephric duct. The movement of ureteric opening may be because of absorption of terminal part of ureters themselves^[4] which has failed in the present case or it is due to the traction exerted by the kidneys during their ascent the orifice of ureter move superolaterally and ureter enter obliquely through the base of bladder^[2]. The tubules showing tall columnar ciliated epithelium may be an attempt towards formation of collecting ducts.

References:

1. Collins P.: Gray's Anatomy In: Embryology and development, 38th Edition, Churchill Livingstone London, 2000: 91-128.
2. Moore K. L., Persaud: The developing human clinically orientated embryology in: Urogenital system, 6th Edition, Harcourt Asia Pvt. Ltd. LTD, 1998: 311-316.
3. William J. Larsen. Human Embryology in development of urogenital system. 4th Edition, Churchill Livingstone, Elsevier, 2009: 493-494.
4. Hamilton W. J. and Mossman H. W.: Hamilton, Boyd and Mossman's Human Embryology prenatal development of form and function in: Urogenital system, 4th Edition, The Macmillan Press Ltd. The Williams and Wilkins Company, 1972: 377-397.

