

PHRENIC NERVE PALSY AFTER SUPRACLAVICULAR BRACHIAL PLEXUS BLOCK

Dr.Arun Kr. Gupta, Dr.D.S.Divekar, Dr.V.K.Dhulkhed, Dr.Madhur,
Dr.Vivek Shrivastav.

ABSTRACT

A 67 year old male patient was scheduled for implant removal from right upper limb under supraclavicular block. During procedure patient develops right phrenic nerve palsy & complains of dyspnea which was managed conservatively and no intervention done except chest x-ray for confirming the diagnosis. Surgeons completed the implant removal without any invasive intervention or interruption.

Keywords: *phrenic nerve, anatomic variation, supraclavicular block.*

Introduction

With the current trend in upper extremity surgery toward outpatient management, brachial plexus blocks have become valuable in providing effective anesthesia and analgesia to patient's perioperatively^[1]. Interscalene and supraclavicular approaches have been widely studied and regarded as reliable and safe in ambulatory surgery^[1,2] and also for severely ill patients, who benefit from the blockade instead of general anesthesia. No major complications were identified in a review of 1001 supraclavicular blocks performed by staff and resident anesthesiologists in one study^[2].

Despite the popularity of brachial plexus blocks, the surgeon must not forget the rare but severe complications associated with regional anesthesia, including pneumothorax, neurologic injury, vascular penetration, horner's syndrome and phrenic nerve block.

Bigeleisen (2003) reported a case of simultaneous diaphragmatic and brachial plexus stimulation followed

by a successful nerve block and demonstrated the necessity of a thorough knowledge of anatomical variations and standard anatomy for the safe and efficient practice for regional anesthesia^[3].

Some authors admit that phrenic block is always present when the perivascular interscalene technique is used but most of them do not have clinically important repercussions being probably secondary to partial nerve block^[4]. Other authors observed that varying degrees of phrenic nerve block also occur with the supraclavicular and infraclavicular techniques with few clinical manifestations^[5,6].

This article describes a case of a man who underwent a routine supraclavicular brachial plexus block and experienced acute dyspnea due to iatrogenic phrenic nerve palsy. The objective of this report was to present a case of phrenic nerve block without ventilatory compromise in a patient with hypertension posted for the implant removal.

CASE REPORT

A 67-year old male patient, 1.77 m, 76 kg, physical status ASA II, was scheduled for the implant removal from the right upper limb under supraclavicular brachial plexus block (Fig 1).

Address for correspondence:

Dr. Arun Kumar Gupta, Department of Anaesthesia, Rural Medical College, Pravara Institute of Medical Sciences, Loni, Taluka - Rahata, Ahmednagar, Maharashtra-413 736, India.
E-mail: guptaarun@yahoo.com

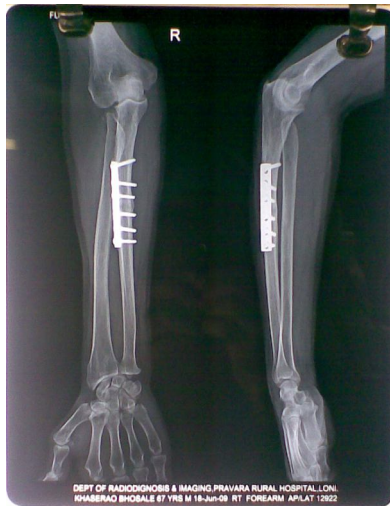

Figure 1: X-ray showing implant in Right Ulna

Pre-anesthetic medication was not administered. In the operating room, venipuncture with a 20G catheter was performed in the left upper limb and normal saline (500 mL) was administered to keep the vein patent. Monitoring consisted of pulse oximetry, ECG and automatic non-invasive sphygmomanometer. The patient was sedated with intravenous fractionated doses of Midazolam (2 mg) and Fentanyl (50 µg). Oxygen (2 L.min⁻¹) was administered via a nasal cannula. The patient was calm, cooperative, with good ventilation, with SpO₂ of 98%. He was positioned for the blockade with his head rotated to the opposite side and right arm close to the body. The area was cleaned and sterile fields were placed around the area of the puncture.

The supraclavicular technique was used to approach the brachial plexus and the site of the injection was determined by the peripheral nerve stimulator (B Braun, Stimuplex, DIG RC) was set at a current of 0.5 mA, a frequency of 2 Hz. The patient's head was turned toward the left and his sternocleidomastoid muscle was identified by having him lift his head off the pillow. The author's index finger was placed posterior to the clavicular head of the sternocleidomastoid muscle and rolled laterally into the groove between the anterior and middle scalene muscles. This groove was traced distally to a position inferior to the omohyoid muscle.

After identifying the appropriate landmarks, a 50 mm, 22 gauge insulated needle (B Braun, Stimuplex) was advanced in a coronal plane posterior to the subclavian artery until a motor response caused supination of the patient's forearm. Simultaneously, the patient reported paraesthesia in his right thumb and the author noticed a motor response in the patient's abdomen at 2 Hz.

The current was decreased to 0.2 mA. After this, the motor response in the patient's forearm disappeared but the diaphragmatic twitch persisted. The latter was assumed to result from direct stimulation of the patient's right phrenic nerve. It was assumed that the block needle was mistakenly placed anterior to the scalenus anticus muscle, and that the motor response in the patient's forearm was from current leak across the plexus sheath rather than from direct stimulation of the plexus roots themselves. For this reason, the needle was removed. The landmarks in the patient's neck were reassessed and the needle inserted several millimeters posterior to the original puncture site. The results changed, a paraesthesia in the hand & supination of the forearm present but motor response of the diaphragm not present this time. Convinced that the plexus had been properly located, we injected 30 ml of bupivacaine (5 mg ml⁻¹) using an immobile needle technique.

Shortly after the administration of the local anesthetic was initiated, the stimulus evoked by the nerve stimulator was abolished. Five milliliters of the anesthetic solution were injected and after a 60 second waiting period the remainder of the anesthetic was injected. At the end of the administration, the patient was alert and oriented, but he complained of dyspnea and short respiratory incursion. On inspection, breathing was predominantly intercostal ipsilateral to the blockade, with retraction of the abdominal wall and tachypnea. Changes from normal to paradoxical motion of the ipsilateral hemidiaphragm were seen. On auscultation breath sounds were absent in the right base. The left hemithorax maintained the same pre-operative pattern. A hypothetical diagnosis of ipsilateral phrenic nerve block was made.

The dyspnea did not worsen and, therefore, non-invasive respiratory support (CPAP or BIPAP) or controlled mechanical ventilation was not necessary. A chest X-ray revealed the right hemidiaphragm at the level of the 6th rib, occupying the right 5th intercostal space. (Figure 2 A, B, C)

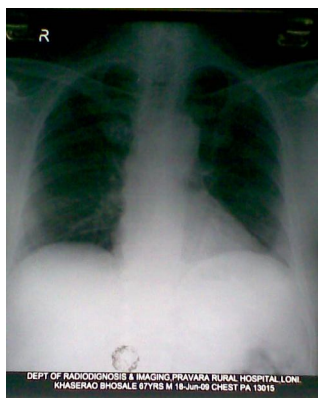

Fig. 2A Pre-op Chest x-ray showing both diaphragms at same level

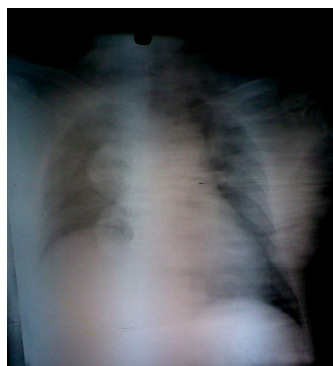


Fig. 2B Intra-op Chest x-ray showing Right Hemidiaphragm at 5th Intercostal space

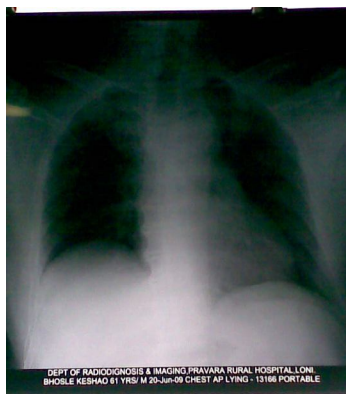


Fig. 2C Post-op Chest x-ray showing Right diaphragm at 7th Intercostal space.

The symptom eventually improved, the blockade was established and the surgery was performed without complaints of pain, discomfort or the need of supplemental analgesia. The surgery lasted approximately 75 minutes. The patient underwent an uneventful removal of implant without additional sedation or local anaesthetic.

At the end of the procedure the patient was transferred to the post-anesthesia recovery unit where there was complete remission of the dyspnea after about two hours, with SpO₂ 96% on room air. Pulmonary auscultation revealed the same preoperative pattern, with breath sounds present in the right base. The brachial plexus block was maintained and the patient did not complain of pain. The patient was kept under observation in the recovery room for three hours.

DISCUSSION

Phrenic nerve palsy is a frequent complication from interscalene plexus blocks^[1,4,7] because roots of the cervical plexus are often anaesthetized with this block. The phrenic nerve, however, is also frequently anaesthetized (36–67%) when a supraclavicular block is performed^[7-9]. This is surprising because the cervical roots are infrequently blocked when a supraclavicular block is performed^[9]. Moreover, the quality of phrenic nerve block differs between the supraclavicular and interscalene approaches. When an interscalene block is used, there is a 100% incidence of diaphragmatic hemiparesis accompanied by a 25% reduction in forced vital capacity (FVC)^[4]. When a supraclavicular block is used, only 50% of patients have diaphragmatic paresis and there is no reduction in FVC^[10].

The brachial plexus is formed by the ventral branches of the inferior cervical nerves, C5 to T1, with or without contributions from C4 and T2. The phrenic nerve originates from the deep cervical plexus, derived from the ventral branches of C2, C3, and C4, being located very close to the brachial plexus in the neck, in front of the anterior scalene muscle, separated from the plexus only by a thin fascia^[4]. Therefore, it can be

reached by the diffusing anesthetic solution when the perivascular interscalene and supraclavicular approaches are used; this is not seen with the perivascular axillary techniques due to the distance between the site of injection and the phrenic nerve. Some authors admit that almost all adverse events resulting from phrenic nerve block are due to extravasation of the local anesthetic out of the musculoaponeurotic cuff or its dispersion towards the cervical plexus, which, in the cuff, is contiguous to the brachial plexus^[3,5]. Thus, if the solution reaches the level between C3 and C5 it spurs the blockade. Not even digital compression above the site of the puncture prevents extravasation of the local anesthetic^[7,10].

Many variations of the phrenic nerve have been described. Rather than descending behind the subclavian vein, the phrenic nerve may also pass anterior to it. An accessory phrenic nerve may arise from roots C5 and C6 or from the nerve to the subclavius muscle. This variation is present in up to 75% of cadavers^[11]. The phrenic nerve may receive branches from the cervical or brachial plexus or arise entirely from the brachial plexus. Cranial nerves XI or XII may also contribute branches. These branches arise in close proximity to the site where supraclavicular block is performed. Thus, when one considers the relatively high frequency of an accessory phrenic nerve or a branch from the brachial plexus itself, there is a significant possibility of anaesthetizing only part of the phrenic nerve with a supraclavicular block. This may lead to a partial block of the ipsilateral hemidiaphragm and is consistent with the outcomes of the study by Neal and colleagues, particularly the preservation of FVC with supraclavicular block even in those patients who have evidence of hemiparesis of diaphragm^[10].

In reality, most healthy patients tolerate ipsilateral diaphragmatic paralysis without any symptoms. It is possible that the accessory musculature compensates the restriction imposed by the paralysis and that expansion of the contralateral lung is able to produce enough negative pressure to ensure good ventilation. Development of dyspnea after brachial plexus block

demands that other causes, such as pneumothorax, recurrent laryngeal nerve block, bronchospasm, allergic reaction, direct neurological lesion and injection in the neuro axis be ruled out. Phrenic nerve block can contribute to trigger the symptoms, respiratory effort and anxiety causing an increase in negative pressure in the upper airways but might not be the only cause of dyspnea. Preoperative sedation with benzodiazepines does not seem to be related with the development of intraoperative dyspnea since in most cases patients seem to be cooperative and alert. Chronic obstructive pulmonary disease (COPD), such as emphysema, is an important co-factor for the development of symptoms. With the destruction of the pulmonary parenchyma, the diaphragmatic movement is important to guarantee the hematosis since a 50% loss in diaphragmatic function will result in dyspnea. In patients with a restrictive pulmonary pattern, the loss of diaphragmatic movements further impairs ventilation and might cause respiratory failure.

In such cases, the X-Ray chest is the most reliable investigation to diagnose phrenic nerve involvement although ultrasound has an added advantage of indicating degree of diaphragmatic incursion i.e. partial or total paralysis^[4].

CONCLUSION

It is a case of simultaneous diaphragmatic and brachial plexus stimulation resulting in a successful nerve block. Regional anesthesia has an expanding role now days in surgery. This case demonstrates the necessity of a thorough knowledge of anatomical variations and standard anatomy for the safe, efficient practice of regional anaesthesia as brachial plexus blocks offer several advantages including providing effective analgesia, reducing narcotic requirements, and facilitating ambulatory care surgery.

In this case, the patient developed complete paralysis of the phrenic nerve with respiratory symptoms which were managed without any intervention, but it is necessary to alert anesthesiologists to restrict the

indication of this technique and be prepared to manage this type of complication.

REFERENCES

1. Klein SM, Evans H, Nielsen KC, Tucker MS, Warner DS, Steele SM. Peripheral nerve block techniques for ambulatory surgery. *Anesth Analg*. 2005; 101(6):1663-1676.
2. Franco CD, Vieira ZE. 1,001 subclavian perivascular brachial plexus blocks: success with a nerve stimulator. *Reg Anesth Pain Med*. 2000; 25(1):41-46.
3. Bigeleisen, P.E. Anatomical variations of the phrenic nerve and its clinical implication for supraclavicular block. *Br. J. Anaesth*. 2003; 91(6):916-7.
4. Urmeý WF, Talts KH, Sharrock NE – One hundred percent incidence of hemidiaphragmatic paresis associated with interscalene brachial plexus anesthesia as diagnosed by ultrasonography. *Anesth Analg*, 1991;72:498-503.
5. Mak PH, Irwin MG, Ooi CG et al. – Incidence of diaphragmatic paralysis following supraclavicular brachial plexus block and its effect on pulmonary function. *Anaesthesia*, 2001;56:352-356.
6. Wilson JL, Brown DL, Wong GY et al. – Infraclavicular brachial plexus block, parasagittal anatomy important to the coracoid technique. *Anesth Analg*, 1998;87:870-873.
7. Knoblanche GE. The incidence and aetiology of phrenic nerve blockade associated with supraclavicular brachial plexus block. *Anaesth Intensive Care*. 1979; 7(4):346-349.
8. Farrar MD, Scheybani M, Nolte H. Upper extremity block, effectiveness and complications. *Reg Anesth* 1981; 6: 133–4
9. Lanz E, Theiss D, Jankovic D. The extent of blockade following various techniques of brachial plexus block. *Anesth Analg* 1983; 62: 55–8
10. Neal JM, Moore JM, Kopacz DJ, Liu SS, Kramer DJ, Plorde JJ. Quantitative analysis of respiratory, motor, and sensory function after supraclavicular block. *Anesth Analg* 1998; 86: 1239–44
11. Bergman RA, Thompson SA, Afifi Ak, Saadeh FA. *Compendium of Human Anatomic Variation*. Baltimore: Urban & Schwarzenberg, 1988; 138–139

