

RARE CASE OF CYSTICERCOSIS OF RECTUS ABDOMINIS MUSCLE PRESENTING AS PELVI ABDOMINAL LUMP DURING PUERPERIUM

Bangal V* , Kwatra A* , Garg S*.

Abstract

Cysticercosis is a parasitic disease caused by Taenia solium. It is a major public health problem in developing countries. Infection is acquired through ingestion of raw or undercooked meat containing the cysticercus. Man is the intermediate host and pig is definitive host. Cases usually present with vague abdominal discomfort, indigestion and diarrhoea. Cysticerci can be found anywhere in the body, but are most commonly detected in brain, eye, skeletal muscle and subcutaneous tissue. Diagnosis is made by the demonstration of eggs or proglottids (Fig. 1) in faeces and definitive diagnosis is by biopsy of the lesion. We report an unusual case, who presented with a pelvi - abdominal lump during puerperium. Diagnosis of cysticercosis of rectus abdominis muscle was confirmed by histopathology. She was treated by surgery and pharmacotherapy.

Key Words : *Cysticercosis , Pelvi-abdominal lump.*

Introduction

Cysticercosis caused by *T. solium* larva is a major public health problem in developing countries. It is endemic in south east Asia, central and south America and Africa.^[1] In humans, the organisms penetrate the intestinal wall and invade subcutaneous tissue, brain, eye, muscle, heart, liver, lung and peritoneum. Cysticercosis is common in communities, where pigs are allowed to roam freely, residents consume undercooked pork and basic sanitary facilities are lacking. Neurocysticercosis is the most common parasitic infestation. Human is the only definitive host of *T. solium*, harbouring adult tapeworm in intestine, where as both man and pig can act as intermediate host and harbour the larvae in different internal organs². Human and pig , both acquire cysticercosis through ingestion of eggs excreted in feces by human carrier. Living larvae evade immune recognition

and do not elicit inflammation. When the larvae die, they induce a vigorous granulomatous inflammatory response that may produce symptoms depending upon anatomic location.^[3] Although most reported cases of cysticercosis involve the brain, this report describes a case of rapid onset lump in abdomen due to *Taenia solium* during puerperium.



Fig 1: Showing proglottids

* Dept of Obs & Gynae, RMC, Loni.

Address for correspondence:

Dr V. Bangal, Department of Obs & Gynae, Rural Medical College, Pravara Institute of Medical Sciences, Loni-413736, District- Ahmednagar, Maharashtra (India).

E-mail:vbb217@rediffmail.com

Case report

A 25 years old woman , Gravida 2, Para 1, Live 1 with full term gestation presented in active labour. She delivered a full term male baby of

2.725 Kg. Her intrapartum and immediate post partum period was uneventful. She was discharged from hospital on 4th postnatal day. She again presented on the 11th postnatal day with complaints of pain in abdomen and fever since 2 days. On examination, vitals were stable, abdomen was soft, no palpable mass was felt, but there was marked tenderness in both the iliac fossa. A provisional diagnosis of puerperal pyrexia was made. Routine investigations were within normal limits. Erythrocyte sedimentation rate (ESR) was raised i.e. 67mm, Blood and urine culture was sterile after 48 hours. Ultrasonography of abdomen - pelvis revealed mild collection in Morrison's pouch, splenorenal recess and pelvic cavity. She was started on parental antibiotics i.e. Injection cefotaxime, metronidazole and gentamicin. She got symptomatic relief and was discharged from hospital on request after 5 days.

She again got admitted after 2 days (on 17th postnatal day) with complaints of pain in abdomen and lump in lower abdomen since 24 hours. Examination revealed marked tenderness in both the iliac fossa. A 12 x 5 cm cystic mass felt in right iliac fossa. Uterus could not be felt separately from the mass. A similar mass of about 9 x 5 cm cystic in nature felt in left iliac fossa (Fig. 2). On per vaginal examination, there was fullness in pouch of douglas and soft boggy mass was felt in posterior fornix. A provisional diagnosis of ovarian cyst was made.

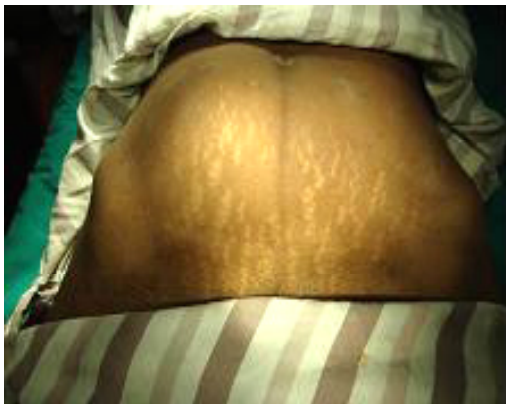

Fig. 2 Showing abdominal lump

Ultrasonography of abdomen - Pelvis revealed bilateral cystic adnexal lesions with multiple internal septations and debris, suggestive of peritoneal inclusion cyst or loculated ascites or bilateral ovarian cyst. Contrast enhanced computed tomography of abdomen - pelvis showed – bilateral cystic adnexal lesions measuring 12 x 10 x 7 cm³ on right side and 9 x 8 x 5 cm³ on left side, suggestive of endometriotic cyst, peritoneal inclusion cyst or bilateral cystic lesions with bulky involuting uterus (Fig. 3). Patient was started on higher antibiotics (injection cefotaxime, metronidazole & gentamicin). Although patient got symptomatic relief, the mass did not decrease in size.

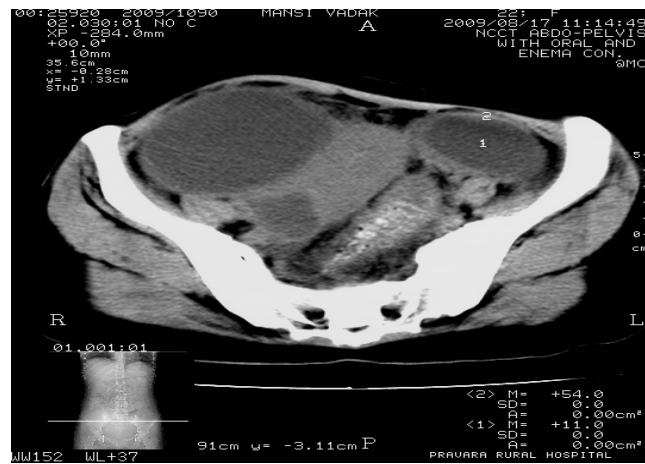

Fig 3: Showing bilateral adnexal lesions on CT scan.

Considering the large size of the cyst, decision of exploratory laparotomy was taken. Intra operatively – there was 12 x 10 cm cystic mass on the right side between the rectus muscle and peritoneum, which got accidentally ruptured while opening the parietal peritoneum. Cyst wall was thick, white and there were multiple small friable daughter cysts inside the cavity (Fig. 4). Uterovesical pouch and pouch of douglas were obliterated by adhesions. In view of the suspicion of hydatid cyst, intraoperative call was given to general surgeon. Left sided cystic ovary was aspirated. Daughter cyst along with cyst wall were sent for histopathology. Post operative period was uneventful. Histopathology report of the cyst wall

revealed cysticercosis of rectus abdominis muscle (Fig. 5). She was treated with tab. Albendazole (400 mg) daily for 21 days. Her x ray skull (Lateral view) and ophthalmic examination were done to rule out evidence of cysticercosis. She was discharged on 11th post operative day.

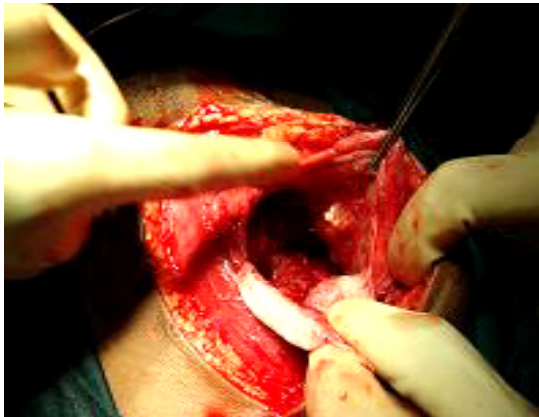

Fig 4: Showing cyst with daughter cysts

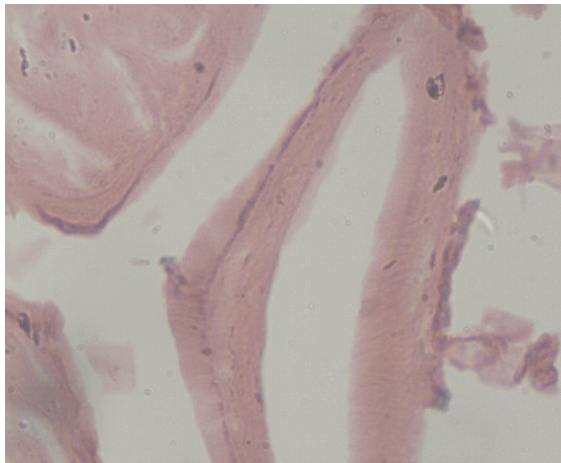


Fig 5: Histopathology slide showing cysticercosis.

Discussion

Presentation of cysticercosis depends primarily upon the anatomic location of the cysts and number as well as the extent of associated inflammatory response. It may manifest as neuro, ocular, muscular and subcutaneous cycticercosis.

Neurological manifestations are most commonly observed. It may manifest as acute seizures, headache, hydrocephalous, chronic meningitis, focal neurological deficit, dementia or spinal cyst. Ophthalmic involvement presents as proptosis, diplopia, loss of vision or slow growing tumour/ nodule with focal inflammation. Muscular involvement may manifest as myalgia, pseudotumour, abscess and rarely pseudohypertrophy.^[3,4] Degeneration of the cyst may result in intermittent leakage of the fluid, eliciting a chronic inflammatory response with collection of fluid around the cyst resulting in formation of a mass or pseudotumour. Alternatively, during the death of the larva, there is leakage of fluid from the cyst.^[5] The resulting acute inflammation results in myalgia and local pain. Muscular cysticercosis is very rare. Mani et al reported a 10×4 cm² well defined eccentric pedunculated structure in the abdominal wall musculature.^[6] In the present case, a 12 x 12 cm² cyst was arising from rectus abdominis muscle. This huge presentation of cysticercosis is very rare. As this case was in her puerperium, and hence was immunocompromised, the immune response of the body did not limit the growth of the mass and presented as huge lump in abdomen. Diagnosis of cysticercosis is confirmed by histopathology. Various other tests used for diagnosis are, stool examination, adhesive cellulose tape anal swab and battery of serological tests like ELISA, indirect haemagglutination test, intradermal test, compliment fixation test, ring precipitation test etc.^[1,7] The optimal treatment of cysticercosis is prevention. Personal hygiene and sanitary health measures are critical to avoid human fecal contamination. In addition, the larvae are destroyed by either freezing or thoroughly cooking pork. Medical management includes various antihelminthics like Albendazole, Praziquantal, Niclosamide.^[2,8] Cysticercosis mostly responds to medical management. Surgical resection is reserved for persistent

disease or cysts in a single location or a very huge size cyst as in this case. The possibility of cysticercosis is rarely considered by the obstetrician while dealing with a case of pelvi – abdominal lump. Common causes of pelvi-abdominal lump in puerperium are ovarian cyst: with or without torsion, acute red degeneration/cystic degeneration/hyaline degeneration of subserous uterine fibroid and loculated ascites .

Conclusion

Cysticercosis of rectus abdominis muscle is rare. Due to its rarity , its presentation as pelvi – abdominal lump pose diagnostic dilemma even after clinical and radiological investigations. This entity must be kept in mind while dealing with cases of pelvi – abdominal cystic lump.

References

1. Evans CAW, Garcia HH. Cysticercosis in : Strickland GT (ed.). Hunter's Tropical Medicine. 8th ed. Philadelphia, PA : WB Saunders Co; 2000:862.
2. Harrison's Principles of Internal Medicine, 17th Edition, volume 1 page, 1272.
3. Brown WJ, Voge M .Cysticercosis : a modern day plague. *Pediatr clin North Am* 1985 ;327:727 -728.
4. Chopra JS, Nand N, Jain K. Generalized muscular Pseudohypertrophy in cysticercosis. *Postgrad Med J* 1986;62:299-300.
5. Scully RE, Mark EJ . Case records of the Massachusetts general Hospital weekly clinicopathological exercises, case 26-1994. *N Engl J Med* 1994;330:1887.
6. Mani NBS , Kalra N et al Sonographic diagnosis of solitary intramuscular Cysticercal cyst. *J clin ultrasound* 2001;29:472-475.
7. Garcia HH, Gonzalez AE, Evans CA, Gilman RH, Cysticercosis Working Group in Peru. *Taenia solium* Cysticercosis. *Lancet*. 2003; 362: 547-56.
8. Maguire, JH. Tapeworms and seizures-treatment and prevention. *N Engl J Med*. 2004; 350:215-7.

