

**QUIZ**  
**[Quiz No. 2, PMR Vol. 05 (2)]**  
**NEURORADIOLOGY**

Gandage S G\*, Shetkar U B\*\*, Aironi V D\*, Sunil N K\*

**Case History**

A twenty-two year old adult came in a state of unconsciousness after consuming dose of oral hypoglycemics by mistake. He had a history of psychiatric disorder and instead of anti-psychotics; he took oral hypoglycemics from medical stores. The blood sugar level then was about 20 mg%. MRI brain was advised and revealed some positive findings. The MR images are as follows:

**What is the positive finding? What is your conclusion?**

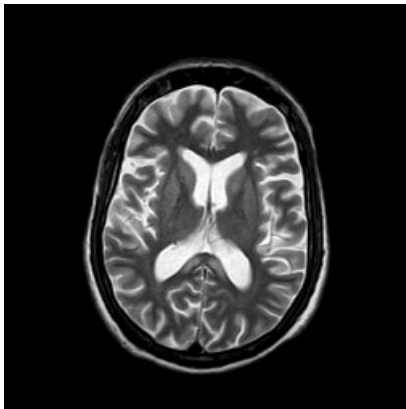


Fig 1: Axial T2 weighted image at the level of corpus callosum

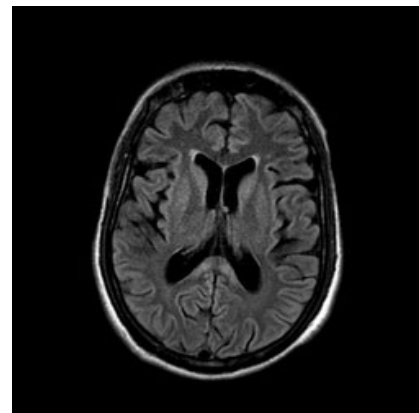


Fig 2: Axial FLAIR image at the same level

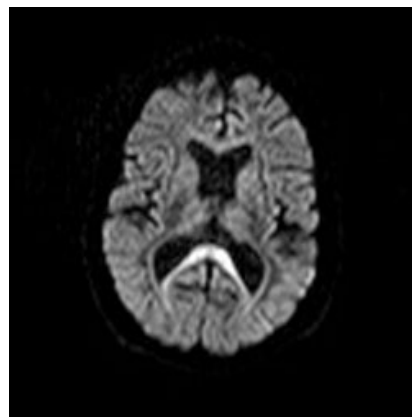


Fig 3: Corresponding Diffusion weighted image of Brain

\* Dept of Radiodiagnosis, RMC, Loni.

\*\* Dept of Medicine, RMC, Loni