

## QUIZ

### [Quiz No. 3, PMR Vol. 05 (3)]

### Obstetric Ultrasound

Aironi V D\*, Sachdev Y S\*\*, Gandage S G\*, Sachdev Y P\*

#### Case History

A twenty-five year old primi-gravida underwent pelvic ultrasound examination. She had history of 3 months amenorrhea, per-vaginal bleeding and pain in lower abdomen of four hours duration. Ultrasound scan was performed on Sonoline G60 S Siemens ultrasound machine with convex probe (3.5 MHz). The following USG images show the underlying condition.

#### What is your diagnosis?

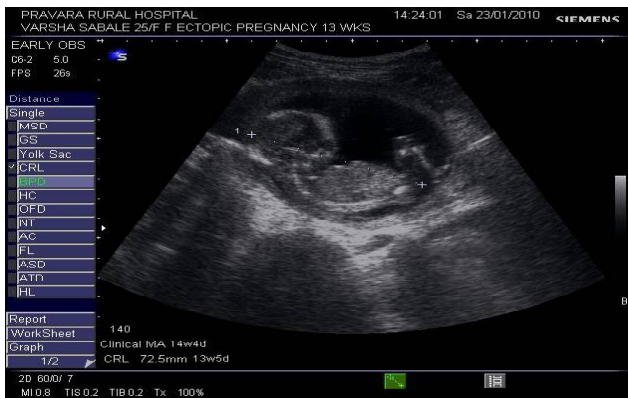

Fig 1: Ultrasound image showing gestational sac with fetus

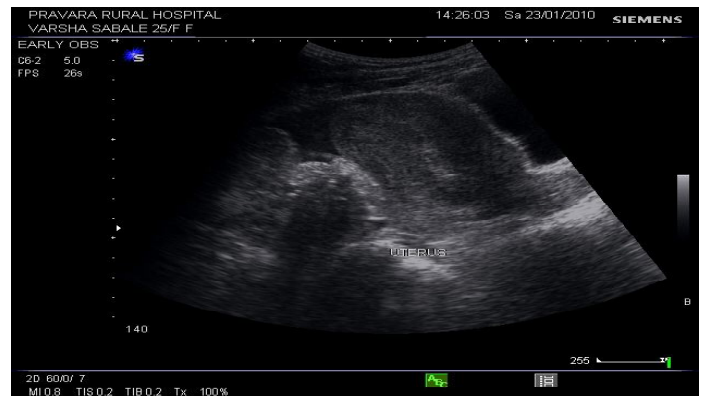

Fig 2: Longitudinal Ultrasound image of uterus

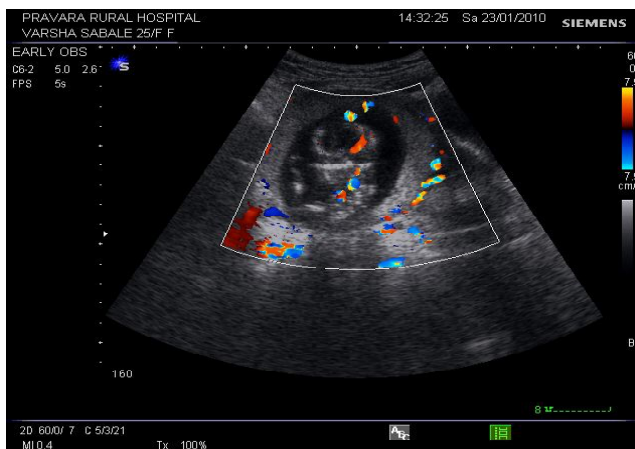


Fig 3: Color Doppler of gestational sac.

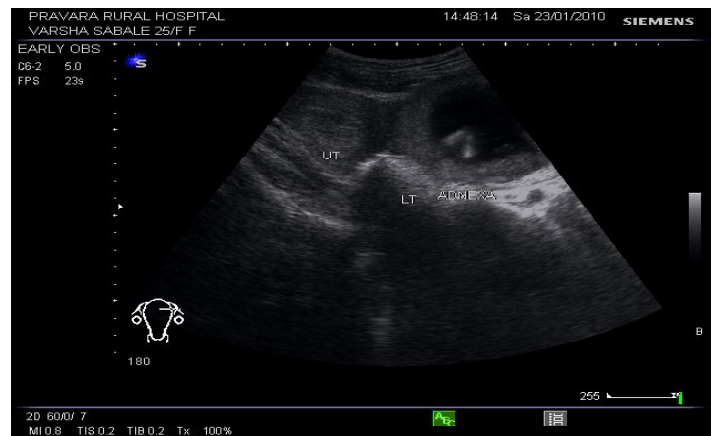

Fig 4: Transverse ultrasound image of uterus and gestational sac

\* Dept of Radiodiagnosis, RMC, Loni.

\*\* Dept of Obs & Gynae, RMC, Loni