

Atypical presentation of capillary hemangioma of upper eyelid : A case report

Nigwekar SP*, Nigwekar PV**

Abstract

Capillary hemangioma is a hamartomatous localized proliferation of vascular tissue in a normal location. It is one of the most common benign eyelid and orbital tumors in children which affects up to 2% of all infants, with a female predilection. They manifest by 1-8 months of age. Most hemangiomas regress spontaneously by age of seven years. Steroids, laser and surgical excision are some treatment options. Recurrence after surgical excision can occur in capillary hemangiomas. Atypical late presentation of capillary hemangioma of left upper eyelid is presented in which meticulous surgical excision provided excellent results.

Key words: Capillary hemangioma, Eyelid tumor.

Introduction

Capillary hemangioma is one of the most common benign eyelid and orbital tumor in children. It may present as a cutaneous, subcutaneous or deep lesion and usually presents at birth or is evident by 6-8 months of age. While capillary hemangioma is usually a clinical diagnosis, orbital ultrasound imaging is especially helpful in subcutaneous and deep lesions to ascertain deeper extension. Most hemangiomas regress spontaneously by age of seven years.^[1] The choice of treatment depends on lesion location, its size and potential adverse effects of the treatment itself. Steroids, laser and surgical excision are some treatment options.

Case Report

A 7 year old male, presented with painless, progressive swelling of left upper eyelid margin of two months duration. Other than left upper eyelid swelling, ophthalmic examination revealed normal anterior and posterior segments in both eyes (BE). There was no significant medical, surgical, family and birth history.

Child was fully immunized as per age. Local examination of left upper eyelid showed a lesion 4mm, soft in consistency and yellowish-white in color. A differential diagnosis of pyogenic granuloma or hemangioma was made and total excision biopsy was carried out under general anesthesia. Histopathological examination of excised lesion confirmed diagnosis of capillary hemangioma. (Figure 1)

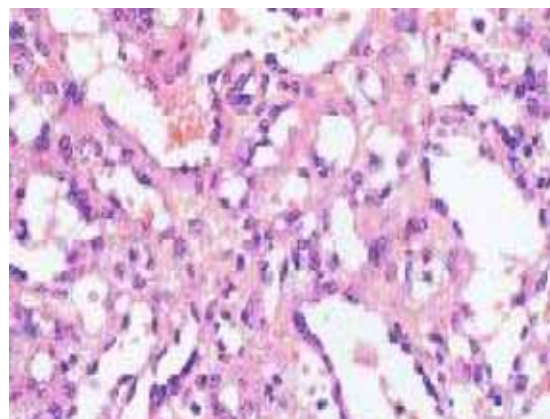


Figure 1: Capillary hemangioma: Histology: Varying sized small vascular channels without true encapsulation.

Patient was discharged with flat lid margin surface. However, one month post operation, patient had reappearance of painful, red, left upper eyelid swelling with mild drooping (Figure 2).

* Assistant Professor, Department of Ophthalmology

** Assistant Professor, Department of Pediatrics,
Rural Medical College, Loni

Address for correspondence:

Dr. Shubhangi Nigwekar
Assistant Professor, Department of Ophthalmology,
Rural Medical College, Loni, Tal. Rahata,
Dist. Ahmednagar, Maharashtra (India)-413736.
Email: drsomenmisra@hotmail.com



Figure 2: Recurrent capillary hemangioma, in left upper eyelid with minimal ptosis.

Ophthalmic examination of both eyes showed normal findings as were seen previously. The recurrent lesion was 10mm in diameter, circular, dome-shaped, red-colored with discrete yellow areas. It was soft and tender (Figure3).

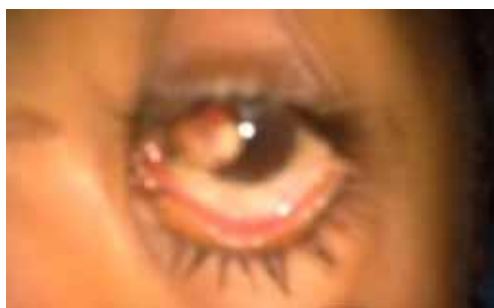

Figure 3: Yellowish-red, circular dome-shaped lesion of capillary hemangioma.

Recurrence of capillary hemangioma with infection was the clinical diagnosis. A total meticulous excision of the mass with good haemostasis using cutting cautery was carried out for the recurrent lesion. Biopsy of the excised mass confirmed the recurrence of capillary haemangioma with infection. Postoperatively local steroid-antibiotic ointment (Ocupol-d) was administered. Follow-up after seven days and after two years showed healed flat scar surface with no recurrence (Figure 4) and (Figure 5)

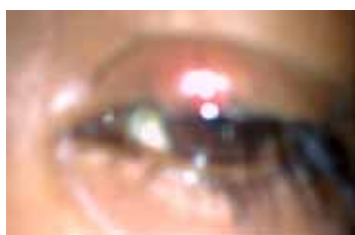

Figure 4: First Postoperative day: Flat surface.

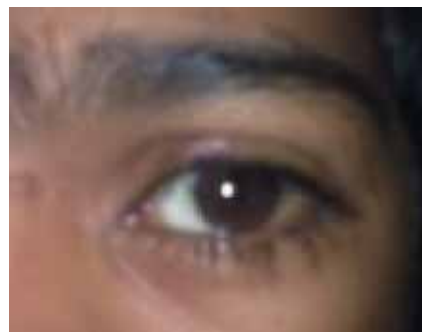

Figure 5: 2 years follow-up : No recurrence of capillary hemangioma.

Discussion

Capillary hemangioma is a hamartomatous localized proliferation of vascular tissue in a normal location. The lesion has a low rate of blood flow and is non-pulsatile. One of the most common benign orbital tumors in children, it affects up to 2 % of all infants, with a female predilection (3:2).^[2] Approximately one-third of capillary hemangiomas are apparent at birth, while the remaining two-thirds manifest by 6 months of age. The history and presentation of a periorbital capillary hemangioma is so typical as to be diagnostic. Parents usually describe a growing red or purple spot that was not present at birth but becomes larger and thicker over the first few months of life. The lesion blanches with pressure, which is helpful in distinguishing it from the non-blanching 'port-wine' stain of Sturge-Weber syndrome. While most hemangiomas are not present at birth, more than half of them will manifest by 1-2 months of age and 90-100% of the lesions will be present by 6-8 months of age. The peak size of the lesion is reached by 6-12 months, at which point the hemangioma, if left untreated, will remain stable for some time before beginning to involute. In fact, spontaneous involution is the rule for untreated capillary hemangiomas and progressive involution continues until 8 years of age. Forty percent of hemangiomas completely regress by 4 years of age and 80% completely regress by 8 years of age.^[3]

Hemangiomas often follow the distribution of the first and second divisions of the fifth cranial nerve. They are usually unilateral and located on the eyelid or

brow and may result in significant ptosis of an involved eyelid. Reduced visual acuity may be noted due to ptosis or astigmatism. Amblyopia is seen in approximately 50% of patients with eyelid hemangioma.^[4] The lesion may be cutaneous or may extend to subcutaneous tissue. The subcutaneous portion may extend into the orbit causing painless, non-pulsating proptosis of the involved eye.^[5]

The ophthalmologist should be aware that many children with periorbital hemangioma may also have intraorbital extension of the lesion and/or systemic angiogenic lesions (including pulmonary, soft-tissue and/or skin lesions). Orbital imaging with B-scan ultrasonography is helpful in determining the posterior extent of suspicious lesions, while chest or abdominal imaging may uncover other hemangiomas. Some patients with large visceral capillary hemangiomas may develop thrombocytopenia, a condition known as Kasabach-Merritt syndrome. Capillary haemangioma with skin haemorrhages, enchondromata of hands and feet and bowing of long bones is known as Maffucci's syndrome.^[6]

Advised Treatment Options

Spontaneous involution is the rule and only observation may be appropriate. In cases of eyelid occlusion leading to amblyopia or significant astigmatism, prompt treatment in the form of occlusion and refractive correction should be initiated.

1. Use of Corticosteroids:

Intralesional, systemic and topical corticosteroids may be used as treatment.

2. Surgical excision:

Surgery carries the risks associated with general anesthesia. As the lesion is not encapsulated, surgical excision is often difficult and there is a risk of recurrence. One has to anticipate intraoperative bleeding and control it with application of cautery.^[7]

3. Laser photocoagulation:

It is effective in attenuating proliferation and facilitating regression of superficial cutaneous hemangiomas of thickness more than 2mm.

4. Immunomodulator:

Vincristine, Cyclophosphamide and Interferon alfa-2a has been used as monotherapy or in combination with systemic corticosteroids.^[7] However myelosuppression, hepatotoxicity and neurotoxicity are the side effects.

Discussion

The present case had a short two month history and late presentation at seven years of age. This is not classic for capillary hemangioma. Clinically the differential diagnosis consists of Pyogenic granuloma. The typical solitary pyogenic granuloma (lobular capillary hemangioma) is a bright red, friable, polypoid papule or nodule ranging from a few millimeters to several centimeters (average size is 6.5mm) in diameter. Bleeding, erosion, ulceration, and crusting are frequently noted. Regressing lesions appear as a soft fibroma. The head, neck and face; distal extremities, especially the fingers (notably in pregnant woman) are the sites of predilection, but lesions can occur anywhere on the integument.^[8] Recurrences after surgical excision can occur in capillary hemangioma as was a feature in our case.

Conclusions

Though capillary hemangioma presents usually at birth and upto 1 year of age, it may present as late as 7 years. Meticulous surgical excision gives good results even in recurrent cases.

References

1. Sihota-Tandon. 'Parson's diseases of eye'. 21st edition 2011:456.
2. Haik BG. Capillary hemangioma. *Surv Ophthalmol* 1994;38(5):399-426.
3. Review of Capillary Hemangioma, Peralta RJ, Glavas. New York University and the Manhattan Eye, Ear and Throat Hospital, New York. *Eye Net Magazine* February 2009.
4. Basak SK. 'Essentials of Ophthalmology', 4th edition 2007: 127.
5. Capillary Hemangioma right upper eyelid: Case report. JM Graff, Adam Garza, KD Carter, January 31, 2006.
6. Kanski JJ. 'Clinical Ophthalmology A Systemic Approach', 6th edition 2007; 105,189.
7. Yanoff M. 'Ophthalmology' 3rd edition 2009: 1462.
8. Dermatologic Manifestations of Pyogenic Granuloma (Lobular Capillary Hemangioma) JC Pierson, DM Elston. *Medscape* 29th April 2010.