

Case report

Cancer Cervix with Brain Metastasis- A rare case from a Rural center of Maharashtra

¹Dr Khushboo Rastogi , ²Dr Vandana Jain , ³Dr Darshana Kawale , ⁴Dr Siddharth Nagshet ,
⁵Dr Gopal Pemmaraju

¹MD Radiotherapy, 3rd year resident, Dept. Of Radiotherapy & Oncology, Pravara Institute of Medical Sciences

²MD Radiotherapy, Head & Professor, Dept. Of Radiotherapy & Oncology, Pravara Institute of Medical Sciences

³DMRT, 2nd year resident, Dept. Of Radiotherapy & Oncology, Pravara Institute of Medical Sciences

⁴MD Radiotherapy, Senior Resident, Dept. Of Radiotherapy & Oncology, Pravara Institute of Medical Sciences

⁵MD Radiotherapy, 2nd year resident, Dept. Of Radiotherapy & Oncology, Pravara Institute of Medical Sciences

Corresponding author- Dr Khushboo Rastogi , Department of Radiotherapy & Oncology , Rural Medical College, PMT, Loni , Email : drkhush.r13@gmail.com

Abstract

Brain metastases from cancer cervix are extremely rare. We report a patient with squamous cell carcinoma of the cervix in a rural setting in western Maharashtra who developed an isolated right parafalcine high frontal metastasis within 6 months of treatment of the primary disease. The presenting symptoms of the metastatic disease were headache, seizures and vomiting. The patient was successfully treated by surgical excision of the metastasis and adjuvant whole brain radiation therapy, and she was disease-free at the 9-month follow-up after treatment of the recurrence.

Keywords-carcinoma cervix, brain metastasis, radiotherapy

Introduction

Cancer cervix is one of the leading causes of cancer deaths among women worldwide and occupies the top rank among cancers in women in the developing countries with an annual incidence of cases in Indian women being

1,34,420. The number of cancer cervix cases registered annually at our rural setup is nearly 100-150.

The various risk factors are early age of first coitus, high risk sexual activities/ multiple sexual partners, high parity, early menopause,

poor hygiene, viral infections with Human Papilloma Virus (HPV), Human immunodeficiency Virus (HIV), smoking, etc.

Cancer cervix usually spreads by local extension and through lymphatics to retroperitoneal lymph nodes. Distant organs are reached by hematogenous dissemination and the most commonly affected distant organs are lung, liver and bone. Metastasis to CNS from cervical cancer is extremely rare; usually seen late in the course of disease and has poor prognosis. [1] The aim of this article is to report this case of brain metastasis from cancer cervix in a rural setup in western Maharashtra and to discuss its clinical features, treatment options and prognosis.

Case Report

A 45 years old female came to observation in March 2014 with complaints of white discharge per vagina since three months. Biopsy from the lesion in March 2014 was suggestive of moderately differentiated squamous cell carcinoma. After a thorough clinic-radiological workup the patient was treated with 50Gy in 25# EBRT with concurrent weekly cisplatin 30 mg/m² followed by ICRT 3# of 7Gy each. Treatment was completed in July 2014 after which patient attained complete remission. Patient remained asymptomatic for six months after completion of treatment.

In January 2015 she experienced sudden onset headache, vomiting, dizziness and seizures. A magnetic resonance imaging (MRI) scan of the

brain done in March 2015 revealed a 2.7 x 3.8 x 3.9 cm neoplastic lesion in the right parafalcine high frontal region (Fig No-1). A metastatic workup was done which included computed tomography (CT) scans of the thorax, abdomen, and pelvis. The workup revealed only metastatic para-aortic lymph nodes. In view of the localized nature of the lesion, surgical excision of the tumor was planned. Patient underwent metastatectomy in April 2015. IHC studies done on the same was suggestive of metastatic poorly differentiated squamous cell carcinoma, consistent with origin in a known primary in the uterine cervix. Patient received 33Gy in 11fractions palliative radiotherapy to whole brain and was then started on palliative chemotherapy with Paclitaxel (175mg/m²) & Carboplatin (AUC-5), every 21 days and received six cycles of the same. Patient remained asymptomatic and in complete remission for 9 months post treatment, after which she defaulted for follow up (Fig No-2).

Discussion

Cancer cervix is a major malignancy of female genital tract and usually spreads to adjacent organs, pelvic and para-aortic lymph nodes. HPV-DNA can be detected in majority of all pre malignant and malignant lesions. The overall incidence of brain metastasis from various malignancies varies from 13.5% to 37%.

Gynecologic malignancies have low propensity to metastasize to brain and the gynecologic malignancy that most commonly metastasizes to

brain is choriocarcinoma. [2] Brain metastasis from cancer cervix is extremely rare with a reported incidence of 0.4%-1.2%. The reported median age at the time of central nervous system metastasis diagnosis was 52 years. [7]

Cerebral metastasis of cancer cervix was first reported by Henriksen in 1949 in an autopsy study. [4] The route of spread to brain is hematogenous (vertebral venous system) which is rare and is responsible for distant metastasis. The development of brain metastasis depends on host immune response, vascularization, number of tumor emboli and characteristics of tumor. [8] Brain metastasis are more commonly seen with poorly differentiated cervical tumors.[1] The distribution of brain metastasis depends on regional blood flow within the brain with a propensity for supratentorial region [1] ; a phenomenon related to vascularity and spatial characteristics of this region.

The reported interval between the initial diagnosis of cervical cancer and presentation of brain metastasis varies; ranging from the first time of diagnosis of primary tumor to 8 years with an overall mean of 3 months. [5]

Clinical presentation of a patient with brain metastasis is likely to depend on the site of lesion; headache and hemi paresis being the most commonly reported symptom and sign. The treatment of brain metastasis usually involves radiation therapy, surgery, or both, depending on the clinical situation. In general, surgical excision is done in those cases with a

solitary lesion or adjacent multiple metastases, cases with diagnostic uncertainty, or with life-threatening and critically located metastases. Patients with nonadjacent, multiple, or inoperable lesions are usually treated with palliative whole brain radiotherapy. Surgical excision of the solitary lesion combined with adjuvant postoperative radiotherapy yields a better survival than radiotherapy alone. [9]

Overall, however, the prognosis of cervical cancer patients with brain metastases is frequently poor. Most studies have reported a median survival of only a few months, but there are a few reports of long-term, disease-free survival in these patients.

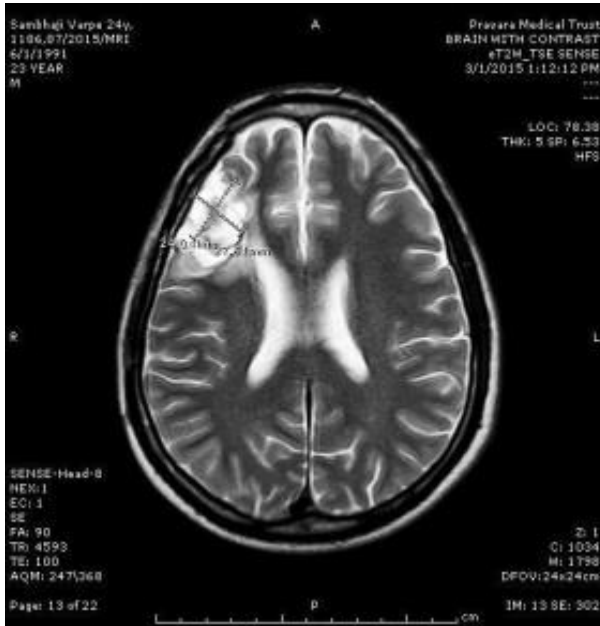
In conclusion, our case provides an example of successful management of brain metastasis in a case of cervical carcinoma, with the use of surgery and adjuvant radiation therapy. This line of treatment should be strongly considered in patients of cervical carcinoma with solitary, resectable brain metastases.

Conclusion

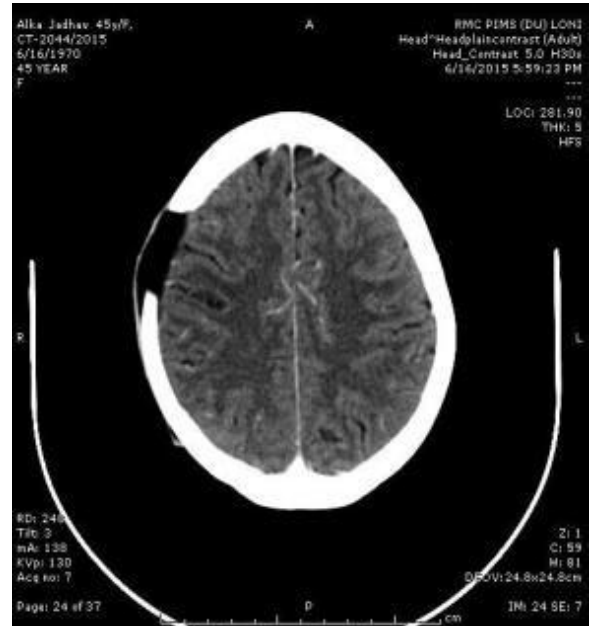
Intracranial metastases in patients with cervical carcinoma are rare, but may occur because survival from the primary tumor is prolonged by the availability of improved treatment facilities. Oncology physicians should keep high degree of suspicion about metastasis if patients develop symptoms. They should be subjected to thorough investigations without delay. A solitary resectable brain metastasis can be successfully treated with surgery or stereotactic radio

surgerys with or without whole-brain radiotherapy. From a review of the literature, the

optimal management of cervical carcinoma with brain metastases is radiotherapy.



Photograph 1



Photograph 2

References

1. Stortbecker TP. Metastatic tumors of the brain from a neurosurgical point of view: a follow-up of 158 cases. *J Neurosurg.* 1954;11:84–111.
2. Yordan LL, Jr, Schlaerth J, Gaddis O, Morrow CP. Radiation therapy in the management of gestational choriocarcinoma metastatic to the central nervous system. *Obstet Gynecol.* 1987;69:627–630.
3. Lefkowitz D, Asconape J, Biller J. Intracranial metastases from carcinoma of the cervix. *South Med J.* 1983;76:519–521.
4. Henriksen E. The lymphatic spread of carcinoma of the cervix and of the body of the uterus. *Am J Obstet Gynecol.* 1949;58:924–942.
5. Cormio G, Pellegrino A, Landoni F, Regallo M, Zanetta G, Colombo A. Brain metastases from cervical carcinoma. *Tumori.* 1996;82:394–396.
6. Saphner T, Gallion H, Nagell JR, Kryscio R, Patchell RA. Neurologic complications of cervical cancer. A review of 2261 cases. *Cancer.* 1989;64:1147–1151.

7. Nielsen SL, Posner JB. Brain metastasis localized to an area of infarction. *J Neuro-Oncol.* 1983;1:191–195.
8. Weed JC, Graff AT, Shoup B, Tawfik O. Small-cell undifferentiated (neuroendocrine) carcinoma of the uterine cervix. *J Am Coll Surg.* 2003;197:44–51.
9. Robinson JB, Morris M. Cervical carcinoma metastatic to the brain. *GynecolOncol.* 1997;66:324–326.
10. Kishi K, Nomura K, Miki Y, Shibui S, Takakura K. Metastatic brain tumors: a clinical and pathologic analysis of 101 cases with biopsy. *Arch Pathol Lab Med.* 1982;106:133–135.
11. Ikeda SI, Yamada T, Katsumata N, et al. Cerebral metastasis in patients with uterine cervical cancer. *Jpn J ClinOncol.* 1998;28:27–29.